



Available online at  
**ScienceDirect**  
[www.sciencedirect.com](http://www.sciencedirect.com)

Elsevier Masson France  
**EM|consulte**  
[www.em-consulte.com/en](http://www.em-consulte.com/en)



Original article

# Anatomical and morphological study of the subcoracoacromial canal



O. Le Reun<sup>a</sup>, J. Lebhar<sup>a</sup>, F. Mateos<sup>b</sup>, J.L. Voisin<sup>d,e</sup>, H. Thomazeau<sup>a</sup>, M. Ropars<sup>a,c,\*</sup>

<sup>a</sup> Orthopedics Department, Pontchaillou University Hospital, 2, rue Henri-Le-Guilloux, 35000 Rennes, France

<sup>b</sup> Anaesthesiology Department, Pontchaillou University Hospital, 2, rue Henri-Le-Guilloux, 35000 Rennes, France

<sup>c</sup> Mouvement Sport Santé (M2S lab), University Rennes 2 – ENS Rennes – UEB, avenue Robert-Schuman, Campus de Ker Lann, 35170 Bruz, France

<sup>d</sup> Département de Préhistoire, Muséum National d'Histoire Naturelle, UMR 7194, USM 103/CNRS, 1, rue René-Panhard, 75013 Paris, France

<sup>e</sup> UMR 7268, Aix-Marseille université, faculté de Médecine-Secteur Nord, boulevard Pierre-Dramard, 13344 Marseille cedex 15, France

## ARTICLE INFO

### Article history:

Received 18 February 2014

Accepted 11 March 2015

### Keywords:

Impingement syndrome

Rotator cuff tear

Scapula

Anatomical study

## ABSTRACT

**Introduction:** Many clinical anatomy studies have looked into how variations in the acromion, coracoacromial ligament (CAL) and subacromial space are associated with rotator cuff injuries. However, no study up to now had defined anatomically the fibro-osseous canal that confines the supraspinatus muscle in the subcoracoacromial space. Through an anatomical study of the scapula, we defined the bone-related parameters of this canal and its anatomical variations.

**Materials and methods:** This study on dry bones involved 71 scapulas. With standardised photographs in two orthogonal views (superior and lateral), the surface area of the subcoracoacromial canal and the anatomical parameters making up this canal were defined and measured using image analysis software. The primary analysis evaluated the anatomical parameters of the canal as a function of three canal surface area groups; the secondary analysis looked into how variations in the canal surface area were related to the type of acromion according to the Bigliani classification.

**Results:** Relative to glenoid width, the group with a large canal surface area (L) had significantly less lateral overhang of the acromion than the group with a small canal surface area (S), with ratios of  $0.41 \pm 0.23$  and  $0.58 \pm 0.3$ , respectively ( $P=0.04$ ). The mean length of the CAL was  $46 \pm 8$  mm in the L group and  $39 \pm 9$  mm in the S group ( $P=0.003$ ). The coracoacromial arch angle was  $38^\circ \pm 11^\circ$  in the L group and  $34^\circ \pm 9^\circ$  in the S group; the canal surface area was smaller in specimens with a smaller coracoacromial arch angle ( $P=0.20$ ).

**Conclusion:** Apart from acromial morphology, there could be innate anatomical features of the scapula that predispose people to extrinsic lesions to the supraspinatus tendon (lateral overhang, coracoacromial arch angle) by reducing the subcoracoacromial canal's surface area.

**Level of evidence:** Anatomical descriptive study.

© 2016 Elsevier Masson SAS. All rights reserved.

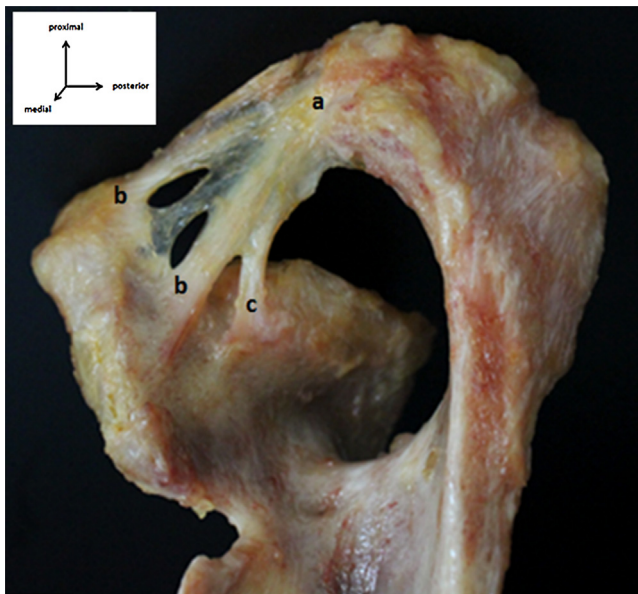
## 1. Introduction

Many clinical anatomy studies have looked into how variations in acromion anatomy are associated with rotator cuff (RC) injuries, mainly for the supraspinatus tendon tears [1–4]. The most common anatomical variations associated with a risk of rupture are the hook-type acromion and a resulting subacromial space reduction.

The supraspinatus tendon is confined by a fibro-osseous canal that is delimited by various structures, not only the coracoacromial ligament (CAL) and the acromion. When the scapula is viewed laterally, the acromion only makes up the posterosuperior edge of this canal. The posteroinferior edge is delimited by the scapular spine; the inferior edge is delimited by the supraglenoid tubercle. The anterior margin is made up of the base of the coracoid process below and the CAL above, with its acromial, coracoid and subglenoid attachments in the multifidus variations (Fig. 1). The supraspinatus tendon runs through a canal that can be called the 'subcoracoacromial canal'. Through an anatomical study of the scapula, we sought to analyse the various bone parameters that were likely to modify the subcoracoacromial canal's surface area and that could induce extrinsic compression of the RC, not only due to the shape of the antero-inferior rim of the acromion, but all of this canal's boundaries.

\* Corresponding author at: Orthopedics and Trauma Department, Pontchaillou University Hospital, 2, rue Henri-Le-Guilloux, 35000 Rennes, France.

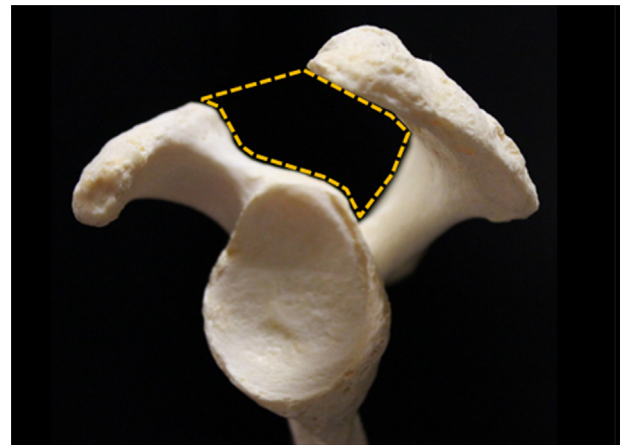
E-mail addresses: [olivier.le.reun@chu-rennes.fr](mailto:olivier.le.reun@chu-rennes.fr) (O. Le Reun), [jonathan.lebhar@chu-rennes.fr](mailto:jonathan.lebhar@chu-rennes.fr) (J. Lebhar), [francois.mateos@chu-rennes.fr](mailto:francois.mateos@chu-rennes.fr) (F. Mateos), [jeanlucvoisin2004@yahoo.fr](mailto:jeanlucvoisin2004@yahoo.fr) (J.L. Voisin), [herve.thomazeau@chu-rennes.fr](mailto:herve.thomazeau@chu-rennes.fr) (H. Thomazeau), [mickael.ropars@chu-rennes.fr](mailto:mickael.ropars@chu-rennes.fr) (M. Ropars).



**Fig. 1.** Dissection showing the coracoacromial ligament in a superomedial view with its attachments: a: acromial; b: coracoid; c: supraglenoid.

## 2. Material and methods

This study with dry bones included 71 scapulas taken from a collection of Caucasian bones. Since all the soft tissues had been removed, we could not determine if any of the specimens had associated RC lesions. With each specimen, the scapula's height and width and the glenoid's height and width were measured with callipers by a single examiner. The average of three consecutive measurements was retained. The scapula specimens were then classified into three types according to Bigliani's classification: type I – flat acromion, type II – curved acromion and type III – hooked acromion. With each specimen, two photographs in lateral and superior orthogonal views were taken with the bones placed on a tripod. To ensure that the scapula's positioning was reproducible, the following criteria were used to ensure correct positioning. On the superior view, the inferior angle of the scapula had to be aligned with the anterior edge of the suprascapular fossa in a plane perpendicular to the glenoid plane. On the lateral view, the scapula image



**Fig. 3.** Subcoracoacromial canal surface area.

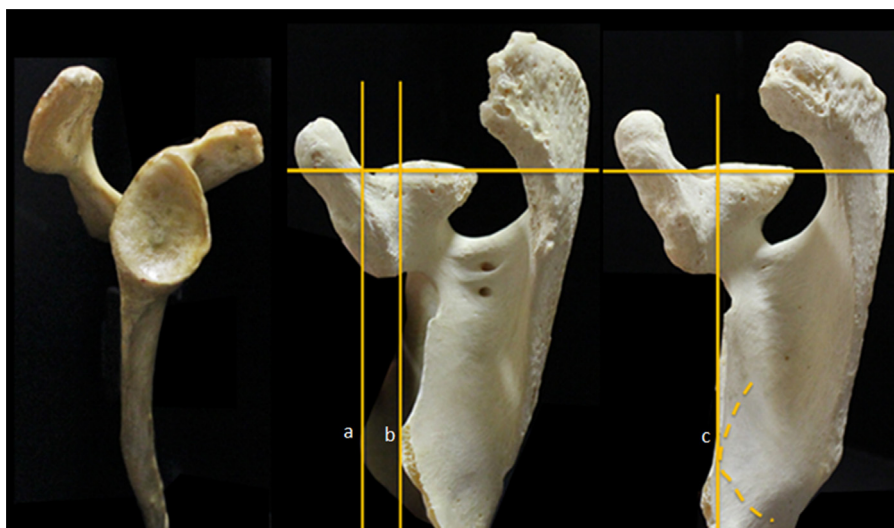had to be taken from the side in the plane perpendicular to the glenoid plane (Fig. 2).

### 2.1. Anatomical parameters of interest

The subcoracoacromial canal surface area corresponded on the lateral view to the surface area included between the superior edge of the glenoid, the anterior edge of the acromion and the scapular spine, the posterior side of the coracoid process and above, the line joining the anterosuperior edge of the acromion to the tip of the coracoid process along the course of the CAL (Fig. 3).

The coracoacromial arch angle was the angle between a line passing through the axis of the coracoid process and a line perpendicular to the glenoid surface, joining the anterior end of the acromion on a superior view (Fig. 4). On the lateral view, the lateral coracoid angle was the angle between a line passing through the axis of the base of the coracoid process and a line passing through the vertical axis of the glenoid (Fig. 4).

The posterior, lateral and anterior acromial overhangs were all measured on the superior view (Fig. 5). The posterior acromial overhang was the distance between the posterior edge of the glenoid and the anterior edge of the acromion on a line passing through the anterior and the posterior edge of the glenoid. The lateral acromial overhang has the distance between the posterior edge of the



**Fig. 2.** Positioning criteria for the scapula on lateral and superior views: a: inferior angle of the scapula; b: anterior overhang of the suprascapular fossa; c: alignment of the two criteria.

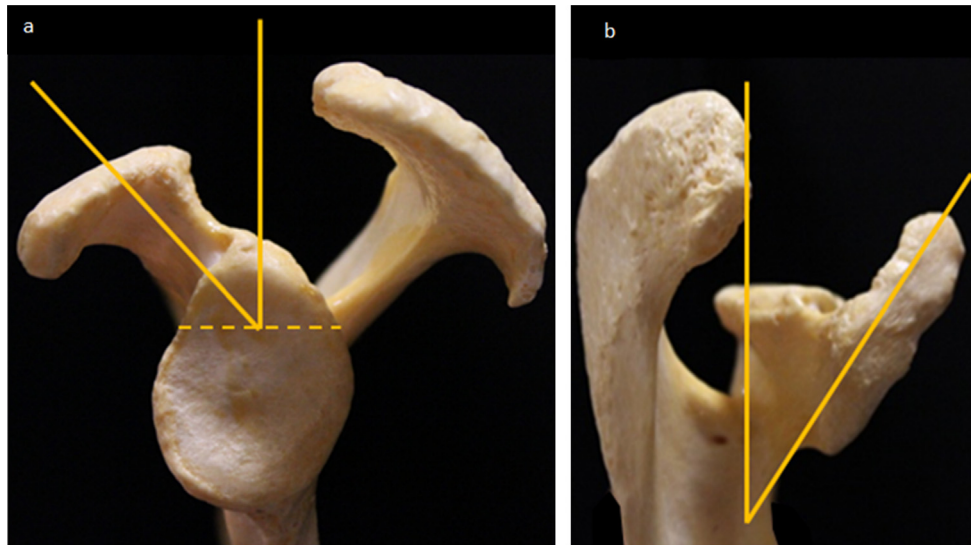


Fig. 4. a: lateral coracoid angle; b: coracoacromial angle.

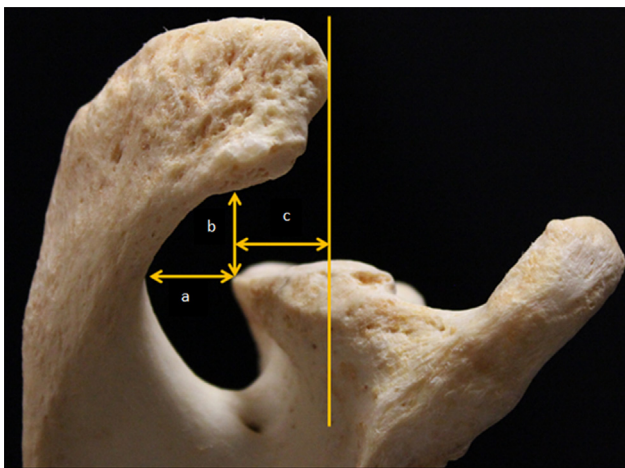


Fig. 5. Acromial overhang measured on a superior view: a: posterior; b: lateral; c: anterior.

glenoid and the medial edge of the acromion on a line perpendicular to the glenoid surface. The anterior acromial overhang was the distance between the posterior edge of the glenoid and the intersection of lines passing through the anterior and posterior edge of the glenoid and a perpendicular line passing through the anterior end of the acromion.

The CAL's length was defined as the distance between the anterior edge of the acromion and the posterosuperior edge of the coracoid process on the lateral view.

## 2.2. Statistical analysis

All of the distances and angles defined on the superior and lateral views of the scapula were measured using image analysis software (ImageJ, a Java-based image processing programme developed at the National Institutes of Health; <http://rsb.info.nih.gov/ij/> accessed on Feb 23, 2016). The measurements were related back to the size of the glenoid, which itself was correlated to subject height. The primary analysis focussed on variations in the canal's surface area as a function of acromion type (Bigliani and Morrison classification). The secondary analysis looked into how various bone parameters altered the subcoracoacromial canal's surface area. For this analysis, the 71 specimens were arbitrarily divided into three

equal canal surface area groups: L group (area > 480 mm<sup>2</sup>)  $n = 21$ , M group (area between 380 mm<sup>2</sup> and 480 mm<sup>2</sup>)  $n = 25$  and S group (area < 380 mm<sup>2</sup>)  $n = 21$ . For each parameter, pairwise comparisons of the average of the three surface area groups and acromion type groups were performed using univariate Student's *t*-test with a significance threshold of  $P < 0.05$ .

## 3. Results

### 3.1. Analysis of bone parameters that modulate the subcoracoacromial canal as a function of acromion type

According to the Bigliani classification, our sample consisted of 25 scapulas with a type I acromion (35.2%), 29 type II (40.8%) and 13 type III (18.3%). In the type I acromion group, the mean canal surface area was  $428 \pm 105$  mm<sup>2</sup>. The mean canal surface area was  $423 \pm 85$  mm<sup>2</sup> and  $442 \pm 88$  mm<sup>2</sup> in types II and III, respectively. There was no significant relationship between the type of acromion and canal surface area (I–II:  $P = 0.85$ ), (II–III:  $P = 0.49$ ), (I–III:  $P = 0.67$ ).

### 3.2. Acromial overhang and acromial morphology

The mean anterior acromial overhang for the type I specimens was  $8.6 \pm 7$  mm; the mean overhang for the type II and III specimens was  $11.4 \pm 6$  mm and  $15.7 \pm 5$  mm, respectively. There was a significant relationship between the anterior overhang and the type of acromion based on the Student's *t*-test (I–II:  $P = 0.04$ ), (II–III:  $P = 0.03$ ) and (I–III:  $P = 0.001$ ). The lateral acromial overhang in scapulas with type III acromion was significantly less than in those with a type I acromion:  $9.3 \pm 5$  mm and  $15.4 \pm 7$  mm, respectively ( $P = 0.01$ ). The mean lateral acromial overhang in scapulas with type II acromion was  $12.3 \pm 6$  mm with (I–II:  $P = 0.08$ ) and (II–III:  $P = 0.10$ ). The posterior overhang for the type I specimens averaged  $11.7 \pm 4$  mm; it was  $11.3 \pm 4$  mm for type II and  $9 \pm 4$  mm for type III. There was no significant relationship between the posterior overhang and the type of acromion (Table 1).

### 3.3. Analysis of bone parameters that modulate the subcoracoacromial canal as a function of surface area

In the L group, the lateral overhang averaged  $12 \pm 6$  mm. The M and S groups had a lateral overhang of  $12 \pm 6$  mm and  $14 \pm 7$  mm, respectively. There was no significant difference in the magnitude

**Table 1**  
Anatomical features of the scapula as a function of the acromion type according to the Bigliani classification.

	Canal surface area (mm <sup>2</sup> )	Anterior overhang (mm)	Posterior overhang (mm)	Lateral overhang (mm)	CAL length (mm)
Type I	428 ± 106	7.6 ± 7.5	1.7 ± 4.3	15.4 ± 7.3	45.3 ± 9.5
I–II ( <i>P</i> -value)	0.85	0.04	0.73	0.08	0.05
Type II	423 ± 86	11.45 ± 6.2	11.3 ± 3.9	12.3 ± 5.7	40.2 ± 9.2
II–III ( <i>P</i> -value)	0.49	0.03	0.09	0.10	0.91
Type III	443 ± 89	15.7 ± 5.1	9 ± 4.1	9.3 ± 5	40.5 ± 8
I–III ( <i>P</i> -value)	0.67	0.01	0.07	0.01	0.12

**Table 2**  
Acromial overhang and canal surface area.

	Posterior overhang (mm)	Lateral overhang (mm)	Anterior overhang (mm)	Posterior overhang/glenoid width	Lateral overhang/glenoid width	Anterior overhang/glenoid width
L group	11 ± 4	12 ± 6	12 ± 7	0.38 ± 0.15	0.41 ± 0.23	0.40 ± 0.26
L–M ( <i>P</i> -value)	0.58	0.85	1	0.93	0.63	0.77
M group	11 ± 4	12 ± 6	12 ± 8	0.38 ± 0.15	0.44 ± 0.22	0.42 ± 0.27
M–S ( <i>P</i> -value)	0.54	0.32	0.16	0.1	0.07	0.41
S group	11 ± 4	14 ± 7	9 ± 5	0.46 ± 0.18	0.58 ± 0.30	0.36 ± 0.23
L–S ( <i>P</i> -value)	0.93	0.28	0.16	0.14	0.04	0.60

of the lateral overhang between the three surface area groups (L–M:  $P=0.85$ ), (M–S:  $P=0.32$ ), (L–S:  $P=0.28$ ). When the lateral overhang was expressed relative to glenoid width, the L group had an average ratio of  $0.41 \pm 0.23$ . This ratio was  $0.44 \pm 0.22$  for the M group and  $0.58 \pm 0.3$  for the S group. When expressed relative to glenoid width, only the lateral overhang was significantly greater in the S group ( $P=0.04$ ) (Table 2).

The coracoacromial arch angle in the L group was  $38^\circ \pm 11^\circ$  on average. The average angle for the M group was  $35^\circ \pm 12^\circ$  and it was  $34^\circ \pm 9^\circ$  for the S group. While not significant (Table 3), the canal surface area was smaller as the coracoacromial arch angle got smaller. The lateral coracoid angle in the L group was  $53^\circ \pm 10^\circ$  on average. The M group had an average angle of  $53^\circ \pm 8^\circ$  and the S group an average angle of  $51^\circ \pm 8^\circ$  (Table 3).

The average CAL length was  $46 \pm 8$  mm in the L group,  $42 \pm 7$  mm in the M group and  $39 \pm 9$  mm in the S group. There was a significant relationship between CAL length and canal surface area ( $P=0.003$ ). The three surface area groups as defined had no significant differences in the ratio of CAL length to glenoid width (Table 3). In the three surface area groups, glenoid height was one-quarter of scapula height.

#### 4. Discussion

Thick, pyramidal and triangular in shape, the supraspinatus muscle spans from the supraspinatus fossa to the superior end of the humerus. It is located below the acromioclavicular joint and the CAL, and above the glenohumeral joint. Together, these anatomical features define a canal, that we called the subcoracoacromial canal [5]. Impingement between the fibro-osseous coracoacromial arch was initially correlated to the acromion's shape by Neer. According to Neer, there is a relationship between RC tears, especially supraspinatus tendon tears, and the hook-type acromion shape

**Table 3**  
Anatomical parameters of the scapula and canal surface area.

	Lateral coracoid angle (°)	Coracoacromial arch angle (°)	CAL length (mm)	CAL length/glenoid width
L group	53 ± 9.6	38 ± 11.3	46 ± 8.39	1.56 ± 0.32
L–M ( <i>P</i> -value)	0.98	0.43	0.16	0.63
M group	53 ± 8.2	35 ± 12.3	42 ± 8.6	1.52 ± 0.27
M–S ( <i>P</i> -value)	0.41	0.67	0.07	0.93
S group	51 ± 8	34 ± 9.1	38 ± 9.3	1.51 ± 0.32
L–S ( <i>P</i> -value)	0.46	0.20	0.003	0.62

[1,3] or the type III acromion defined by Bigliani et al. [2]. The therapeutic principles of anterior acromioplasty are derived from these observations [6–8]. Anetzberger et al. [1] studied the anatomy of the subacromial space after full supraspinatus tears. Using two photographs of anatomical specimens in which the RC status was known, they found a higher RC tear rate in specimens with a hook-type acromion [1]. However, other studies have not found this relationship between the hook-type acromion morphology and RC tears [9,10]. In our study, we also did not find a significant relationship between acromion type and canal surface area. The relationship between the type of acromion and RC tears remains controversial. Moor et al. [10] found no significant differences when they compared acromial shape in patients with and without RC tears. Gill et al. [9] also found no significant relationship between acromial shape and RC pathology in patients above 50 years of age. In a study of the volume occupied by the supraspinatus tendon in the subacromial space [11], the group with subacromial impingement had 7.5% more of the subacromial space occupied by the supraspinatus tendon, while the acromio-humeral distance was unchanged. Uthoff et al. [8] found that changes in the subacromial space can be related to an increased volume of its contents, namely the supraspinatus tendon, which then places abnormal pressure on the CAL [8]. These different observations imply that the antero-inferior acromial overhang described by Bigliani is not sufficient by itself to explain the occurrence of RC tears. Other bone elements in the acromion area or the subcoracoacromial canal could be responsible for extrinsic compression of the supraspinatus tendon resulting from reduced subcoracoacromial canal surface area.

#### 4.1. Main findings

In this study and for the small canal surface areas, the anterior overhang was not greater, in contrast to the lateral overhang.

When comparing the large and medium surface area groups, lateral overhang was larger in the small canal group; when expressed as function of glenoid width, this finding was significant ( $P=0.04$ ).

These findings are reminiscent of the ones by Nyffeler et al. [12] and their description of the (lateral) acromial index, which revealed a relationship between full supraspinatus tears and greater lateral extension of the acromion. By combining the acromial index with glenoid inclination, Moor et al. [10] defined the Critical Shoulder Index (CSI), which measures the acromial coverage relative to the glenoid plane on an anteroposterior view. In their study, the CSI was higher in the group with a RC tear ( $38^\circ$ ) than in the group with an intact rotator cuff;  $33^\circ$  for the control group and  $28^\circ$  for the group with glenohumeral OA. A larger lateral acromial overhang, which is an innate feature of the acromion, could be detrimental to the RC by providing the deltoid with a predominant ascending action. Conversely, the antero-inferior acromial overhang is an acquired feature – a consequence of humeral head elevation with increased loads placed at the vault.

Analysis of the acromial shape reveals significantly greater anterior acromial overhang in type III than type II or I acromions, which is consistent with Bigliani's classification. Conversely, lateral overhang was significantly less in type III acromions and there was no significant relationship between posterior overhang and the Bigliani acromion type. The anterior acromial overhang that is associated with the hook-type acromion shape is an age-dependent process. In fact, Nicholson et al. [13] found an anterior acromial spur in 30% of cadaver specimens above 50 years of age, after examining 420 scapulas.

#### 4.2. Secondary findings

In this study, hook-type acromions (Bigliani type III) did have a significantly smaller subcoracoacromial canal surface area. Like Anetzberger et al. [14], we believe that the size of the subacromial space depends not only on the acromion's shape but also on other anatomical features such as acromial and scapular spine angles [14]. Although it was not significant in our study, the lateral coracoid angle was smaller (more closed) in the group with small canal surface area than in the group with the large canal surface area. A relationship between a smaller lateral coracoid angle and supraspinatus tears was observed by Anetzberger et al. [1]; an acute angle compresses the supraspinatus tendon between the coracoid process and the humeral head [14]. Similarly, the canal surface area was smaller as the coracoacromial arch angle was smaller. This suggests that smaller external coracoid and coracoacromial arch angles are in a position to cause RC tears due to a smaller canal surface area, a source of external compression for the supraspinatus tendon.

Along with the relationship between scapula size and the acromion and CAL length [4], we found a significant relationship between canal surface area and CAL length. The ratio of CAL length to glenoid width was unchanged in the three groups. Given that some studies have shown that shoulders with supraspinatus tears were more likely to have a slender glenoid [1], it seems relevant to study glenoid dimensions as a factor that potentially impacts variations in canal surface area. We observed that no matter the canal's surface area, glenoid height was one-quarter of the scapula height.

This study has certain limitations. The lateral and superior photographs of the scapula do not have the same precision as imaging modalities such as computed tomography or magnetic resonance imaging. Nevertheless, this potential bias was reduced by the use of standardised views, the fact that the same person made all the measurements and the optimised measurement process with image

analysis software. Moreover, the thresholds for the surface area groups were defined arbitrarily, so that the three groups being compared had the same number of specimens in them. Also, using dry bones in this study did not allow us to determine if there was a relationship between anatomical parameters affecting the subcoracoacromial surface area and associated RC tears.

## 5. Conclusion

Certain skeletal elements such as lateral acromial overhang, lateral coracoid angle and coracoacromion arch angle, appear to be the main anatomical features of the scapula that can reduce the space available for the supraspinatus tendon. These elements can be considered as predisposing anatomical factors for supraspinatus tears, to which can be added other intrinsic (thickening of soft tissues) or extrinsic (age-related acromial osteophyte) secondary compression factors. A clinical anatomy study based on CT or MRI definition of the subcoracoacromial canal in specimens with known supraspinatus tendon injury status would be needed to refine the relationship between RC tears and the main anatomical features of the supraspinatus outlet.

## Disclosure of interest

The authors have not supplied their declaration of competing interest.

## References

- [1] Anetzberger H, Maier M, Zysk S, Schulz C, Putz R. The architecture of the subacromial space after full thickness supraspinatus tears. *Z Für Orthop Ihre Grenzgeb* 2004;142:221–7, <http://dx.doi.org/10.1055/s-2004-818780>.
- [2] Bigliani LU, Ticker JB, Flatow EL, Soslowsky LJ, Mow VC. The relationship of acromial architecture to rotator cuff disease. *Clin Sports Med* 1991;10: 823–38.
- [3] Gohlke F, Barthel T, Gandorfer A. The influence of variations of the coracoacromial arch on the development of rotator cuff tears. *Arch Orthop Trauma Surg* 1993;113:28–32.
- [4] Stuart MJ, Azevedo AJ, Cofield RH. Anterior acromioplasty for treatment of the shoulder impingement syndrome. *Clin Orthop* 1990;260:195–200.
- [5] Rouvière H, Delmas A. *Anatomie Humaine Descriptive, Topographique et Fonctionnelle*. Ed. Masson-Elsevier, Paris.
- [6] Gartsman GM, Blair ME, Noble PC, Bennett JB, Tullos HS. Arthroscopic subacromial decompression. An anatomical study. *Am J Sports Med* 1988;16:48–50.
- [7] Neer CS. Anterior acromioplasty for the chronic impingement syndrome in the shoulder. 1972. *J Bone Joint Surg Am* 2005;87:1399, <http://dx.doi.org/10.2106/JBJS.8706>.
- [8] Uthoff HK, Hammond DI, Sarkar K, Hooper GJ, Papoff WJ. The role of the coracoacromial ligament in the impingement syndrome. A clinical, radiological and histological study. *Int Orthop* 1988;12:97–104.
- [9] Gill TJ, McIrvine E, Kocher MS, Homa K, Mair SD, Hawkins RJ. The relative importance of acromial morphology and age with respect to rotator cuff pathology. *J Shoulder Elbow Surg* 2002;11:327–30, <http://dx.doi.org/10.1067/mse.2002.124425>.
- [10] Moor BK, Wieser K, Slankamenac K, Gerber C, Bouaicha S. Relationship of individual scapular anatomy and degenerative rotator cuff tears. *J Shoulder Elbow Surg* 2014;23:536–41, <http://dx.doi.org/10.1016/j.jse.2013.11.008>.
- [11] Michener LA, Subasi Yesilyaprak SS, Seitz AL, Timmons MK, Walsworth MK. Supraspinatus tendon and subacromial space parameters measured on ultrasonographic imaging in subacromial impingement syndrome. *Knee Surg Sports Traumatol Arthrosc* 2015;23:363–9, <http://dx.doi.org/10.1007/s00167-013-2542-8>.
- [12] Nyffeler RW, Werner CML, Suktharankar A, Schmid MR, Gerber C. Association of a large lateral extension of the acromion with rotator cuff tears. *J Bone Joint Surg Am* 2006;88:800–5, <http://dx.doi.org/10.2106/JBJS.D.03042>.
- [13] Nicholson GP, Goodman DA, Flatow EL, Bigliani LU. The acromion: morphologic condition and age-related changes. A study of 420 scapulas. *J Shoulder Elbow Surg* 1996;5:1–11.
- [14] Anetzberger H, Putz R. Morphometry of the subacromial space and its clinical relevance. *Unfallchirurg* 1995;98:407–14.